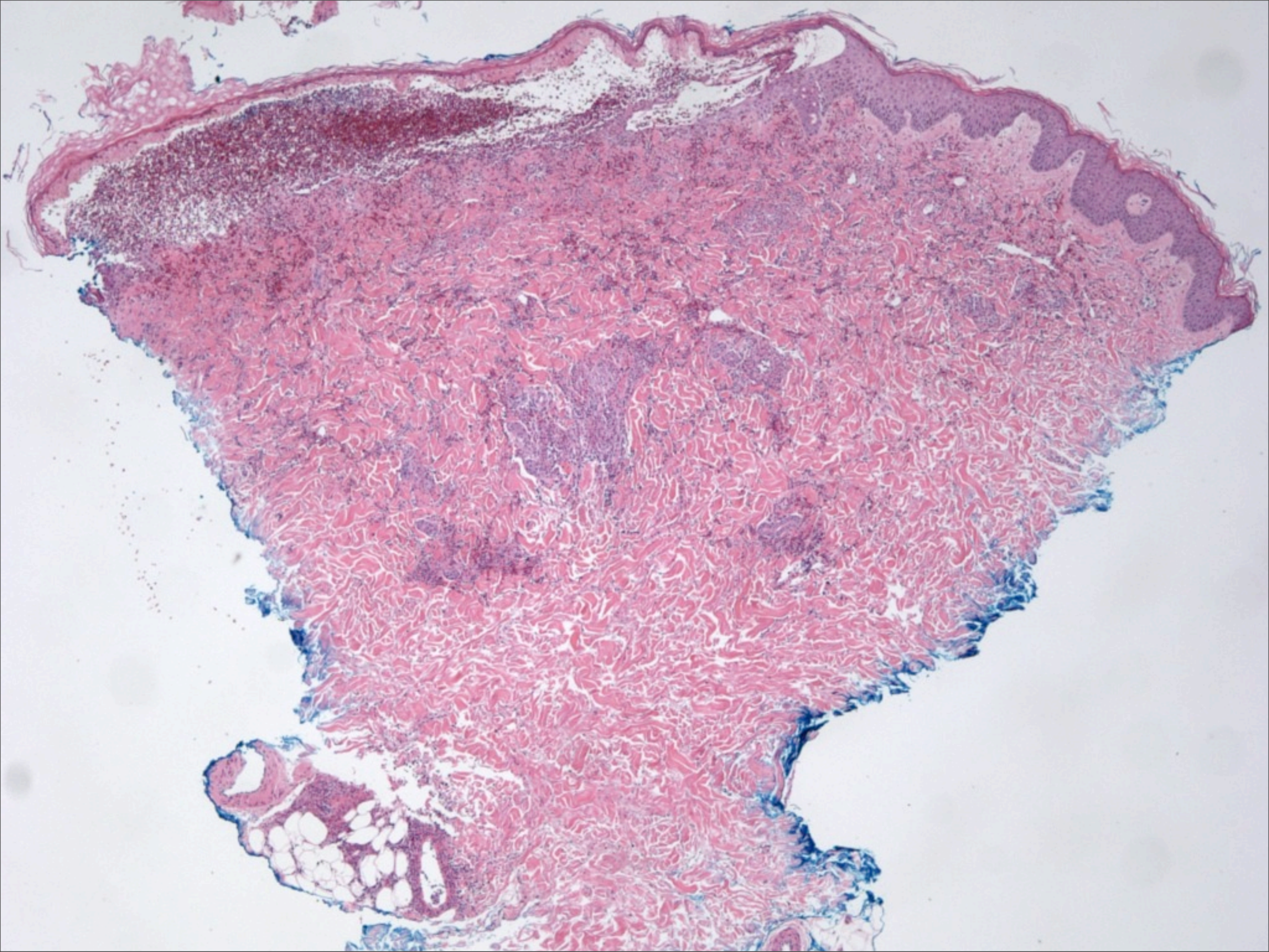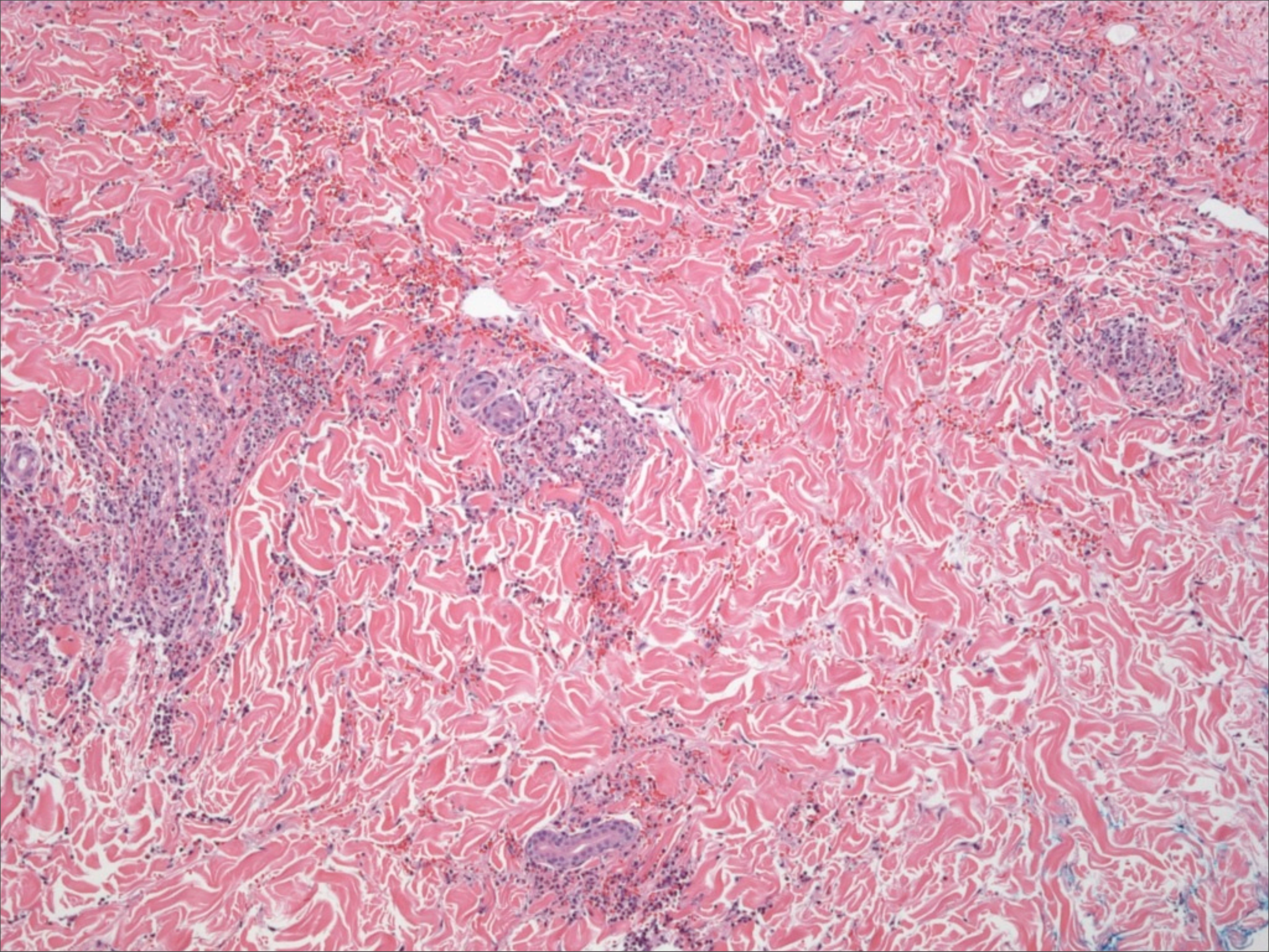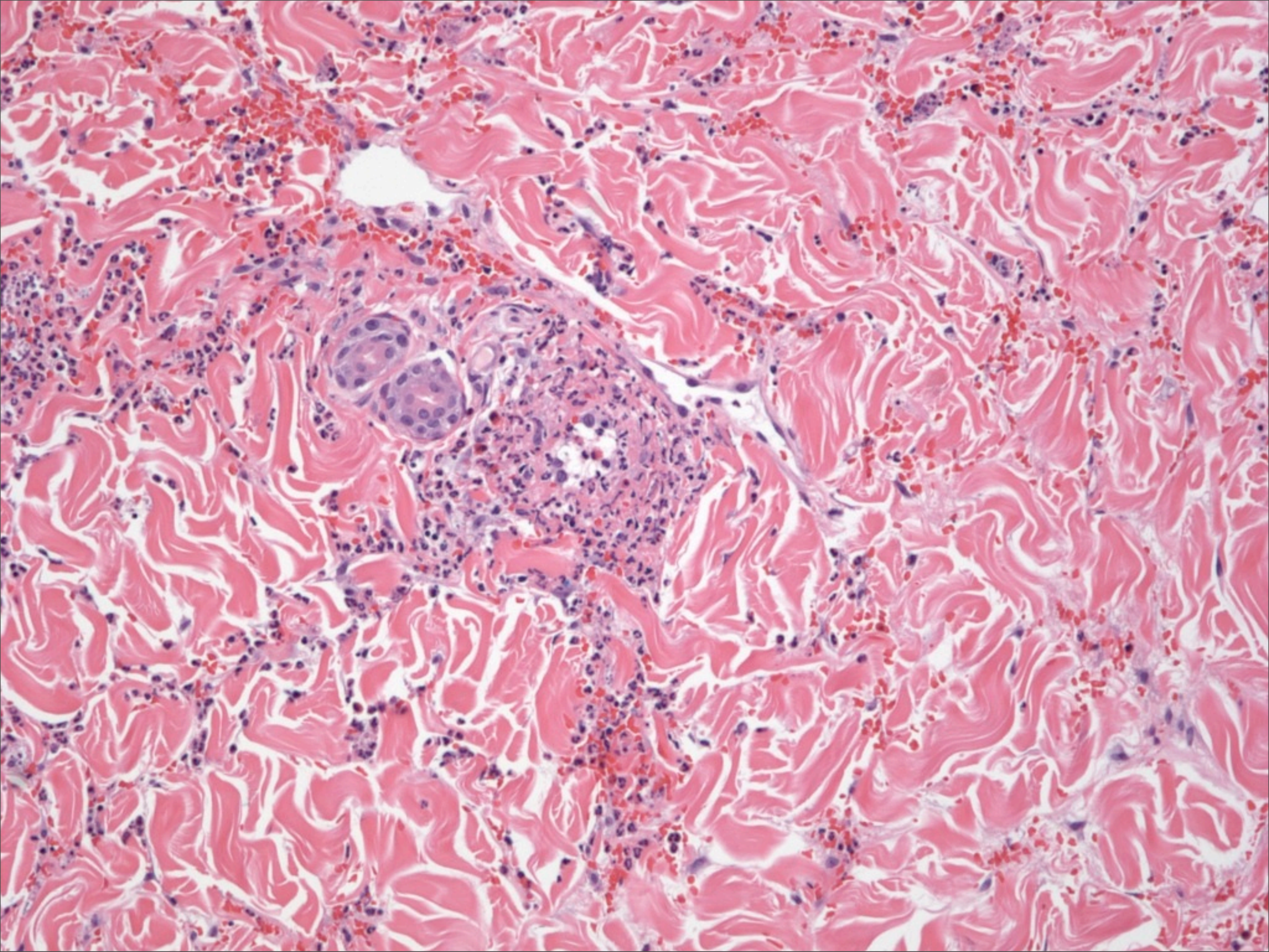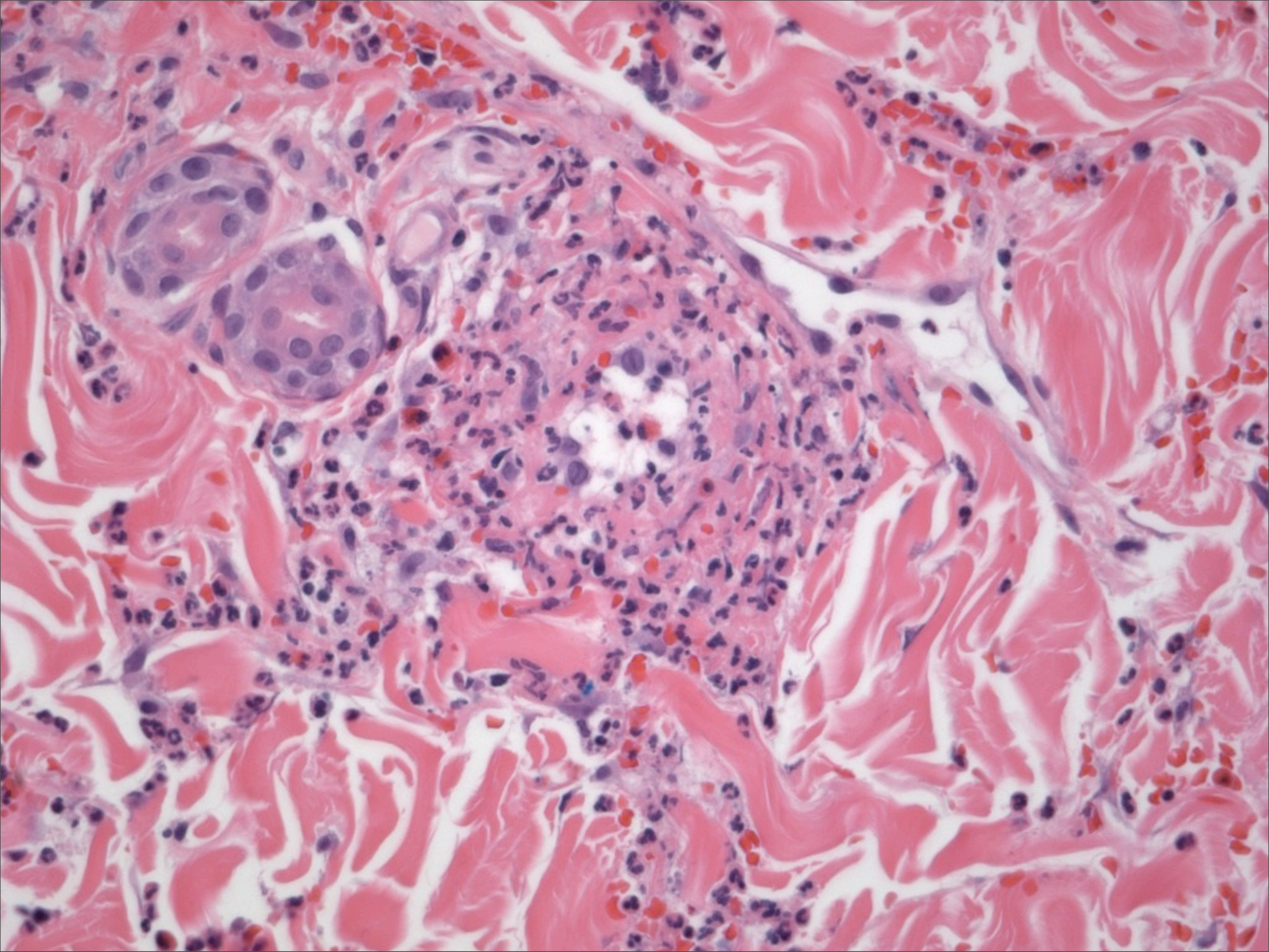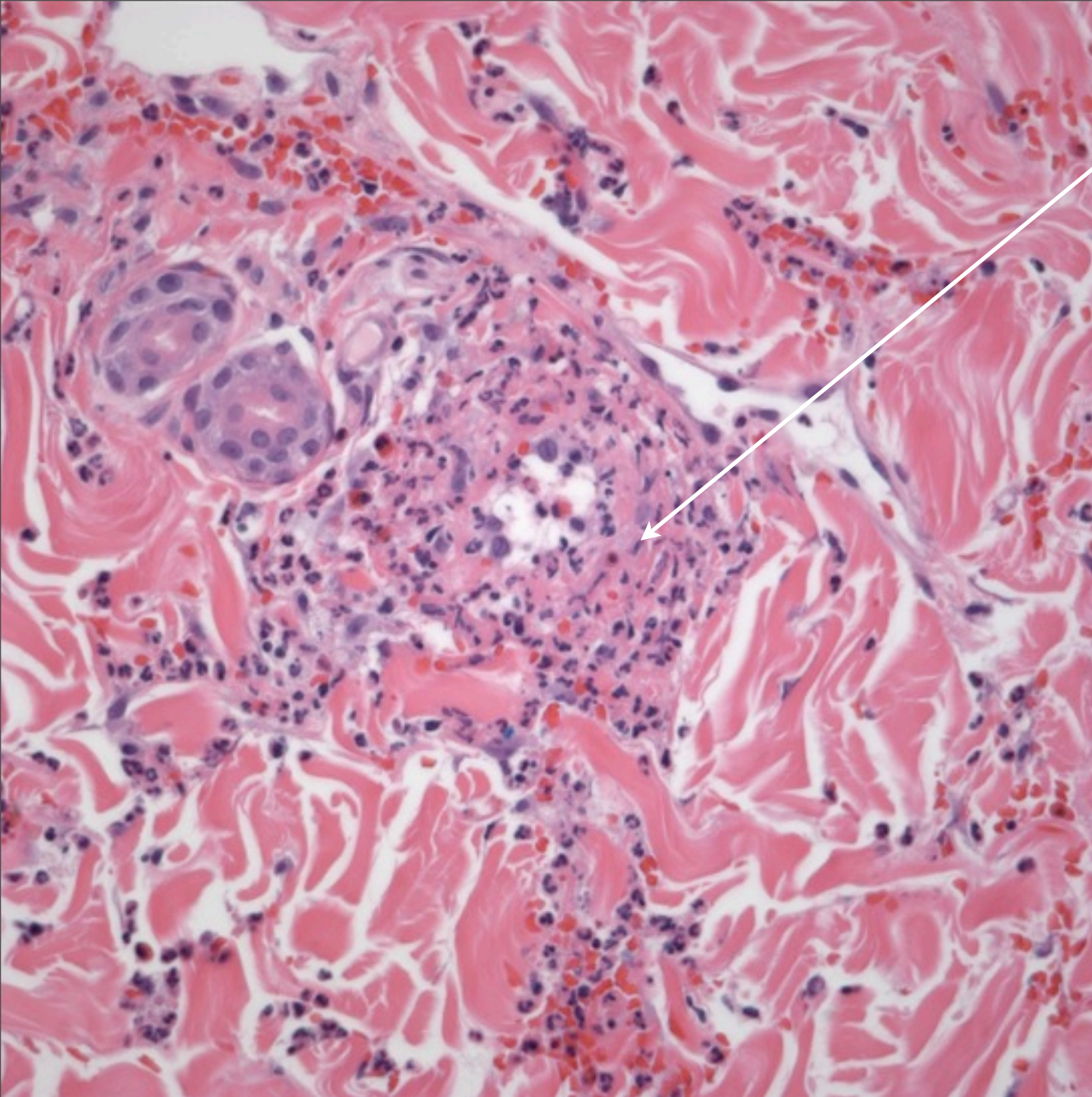


Leukocytoclastic Vasculitis



Must have fibrinoid
necrosis of vessels!

Secondary changes of nuclear dust and hemorrhage
May show bullous changes